

IMAGING PERFORMED BY

IntraPet.com



Clinical Sonography & Telecytology

EDUCATIONAL TELECONSULTATION SERVICES™

1-800-838-4268 info@sonopath.com SonoPath.com

PATIENT

Bonnie Kaplan

SPECIES

Feline

BREED

DSH

SEX

Female Spayed

AGE

8.3.05

WEIGHT

5.69lbs

INTERPRETED BY

Maggie Machen Lamy,
DVM, DACVIM
(Cardiology)

HOSPITAL NAME

Everhart Veterinary
Hospital

REFERRING VET

Dr. Hess

INVOICE

25089

DATE

6.30.22

PRESENTING CLINICAL SIGNS

History: Progressive weight loss, intermittent GI signs.

-Current medications: Provable.

-Blood pressure:

-Sedation used: Not required to complete full diagnostic ultrasound.

-Pertinent previous ultrasound results:

-STAT: Not requested

-Imaging performed by: Andi Parkinson, BS, RDMS.

ECHOCARDIOGRAM FINDINGS

2D, m-mode, color flow and doppler imaging is available. The left ventricular wall is normal in dimension with region of irregularity. There is a mildly hyperechoic endocardium consistent with mild fibrosis. The endocardium also appears mildly remodeled. The papillary muscles are normal in size and hyperechoic. The left atrium is normal in size. The right atrium is normal in size. The right ventricle appears normal. The mitral valve is normal in structure and mobility. No obvious valve regurgitation. Blood flow through both the LVOT and RVOT is normal in velocity. No pleural or pericardial effusion seen. No obvious cardiac tumors.

CARDIAC CHART

FELINE CARDIAC PARAMETERS	BODY WEIGHT (kg)	HR (BPM)	IVSd (cm) <small>(Moise, Pipers)</small>	LVIDd (cm) <small>(Moise, Pipers)</small>	LVWd (cm) <small>(Moise, Pipers)</small>	FS (%)	EF (%)
NORMAL PARAMETER	-----	150-240	3.5-0.55	<2 (mean 1.5)	3.5-0.55	35-67	80-100
PATIENT	2.6	220	0.34	1.3	0.38	61	92
FELINE CARDIAC PARAMETERS	LA/AO <small>(Boon)</small>	LA/AO HEART BASE (Swe) <small>(Abbott)</small>	LA 2D short axis Base view (cm) <small>(Abbott)</small>		LVOT VEL (m/s)	RVOT VEL (m/s)	E max (m/s)
NORMAL	<1.5	<1.3	<1.2		<1.6	<1.3	<0.9
PATIENT	NM	1.2	1.1		0.8	NM	NM

Adapted from June Boon, Veterinary Echocardiography, 1998
Abbott J & MacLean H JVIM 2006;20: 111-119, Moise et al. Am J Vet Res 47:1476, 1986. Pipers et al. Am J Vet Res 40:882, 1979.

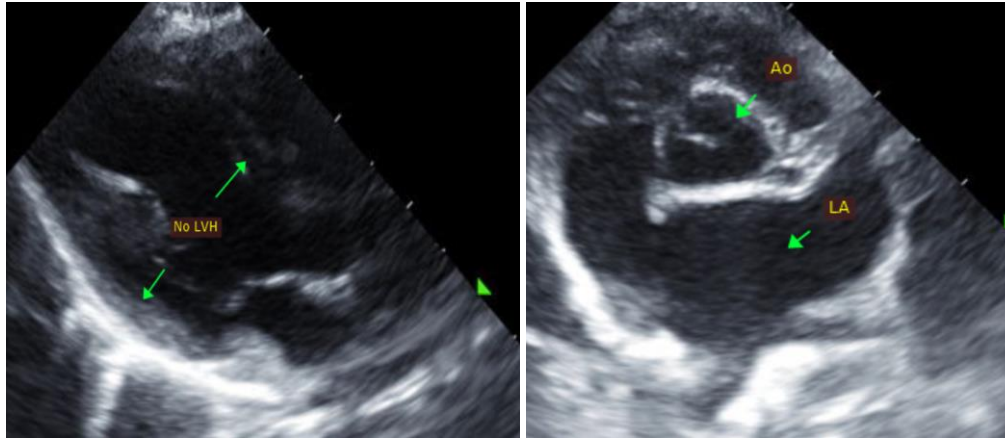
INTERPRETATION OF THE FINDINGS & FURTHER RECOMMENDATIONS

Overtly normal cardiac structure and function. The LV wall thickness is normal, and there is no evidence of elevated left atrial pressure or underlying pathology at this time. There is mild remodeling and fibrosis of the left ventricular wall, which is considered likely a normal age-related finding. Given these findings, no medications are indicated.

Anesthetic risk is considered mild. With remodeling and diastolic stiffening, there is an elevated risk for fluid overload in this patient and judicious IV fluid use is recommended. Heart rate stimulating drugs such as atropine, glycopyrrolate or ketamine should be avoided unless medically necessary. Risk for complication with steroid use typically follows LA dilation, which in this case is low. That being said, any cat can experience unexpected signs of intolerance and monitoring of RR/RE is advised particularly in the initiation phase.

Recommend recheck echocardiogram in 1 year to assess for any progressive issues.

IMAGES



The information and recommendations provided are based on the images presented by the referring veterinarian. No evaluation can be communicated regarding pathology that was not visible in the image/video clips provided.

Thank you for this referral. This report was generated using transcription software, and minor dictation errors may be present. If the clinical or image interpretation does not parallel your findings or if I can be of any further assistance, please contact me.

Maggie Machen Lamy, DVM
Diplomate of the American College of Veterinary Internal Medicine (Cardiology)
info@sonopath.com